



Development of Complex Curricula for Molecular Bionics and Infobionics Programs within a consortial* framework**

Consortium leader

PETER PAZMANY CATHOLIC UNIVERSITY

Consortium members

SEMMELWEIS UNIVERSITY, DIALOG CAMPUS PUBLISHER

The Project has been realised with the support of the European Union and has been co-financed by the European Social Fund ***

**Molekuláris bionika és Infobionika Szakok tananyagának komplex fejlesztése konzorciumi keretben

***A projekt az Európai Unió támogatásával, az Európai Szociális Alap társfinanszírozásával valósul meg.





Peter Pazmany Catholic University

Faculty of Information Technology

www.itk.ppke.hu

BEVEZETÉS A FUNKCIONÁLIS NEUROBIOLÓGIÁBA

INTRODUCTION TO FUNCTIONAL NEUROBIOLOGY

By Imre Kalló

Contributed by: Tamás Freund, Zsolt Liposits, Zoltán Nusser, László Acsády, Szabolcs Káli, József Haller, Zsófia Maglóczky, Nórbert Hájos, Emilia Madarász, György Karmos, Miklós Palkovits, Anita Kamondi, Lóránd Eröss, Róbert Gábrriel, Kisvárdai Zoltán

Movement disorders

Imre Kalló & Anita Kamondi

Pázmány Péter Catholic University, Faculty of Information Technology

- I. Brain regions and pathways involved in motor control.
- II. Disturbance of motor control at the level of
 - basal ganglia (Parkinson's disease)
 - cerebellum (Spinocerebellar ataxia and essential tremor)
 - cerebral cortex (Apraxia)

Elements of voluntary movements

1. Decision of movement
2. Activation of the adequate motor pattern
3. Planning of movement
4. Starting the movement
5. Execution of movement

Continuous adaptation of the muscle tone to the movement

Continuous sensory control of the movement

6. Termination of movement

Structures of the nervous system controlling movement

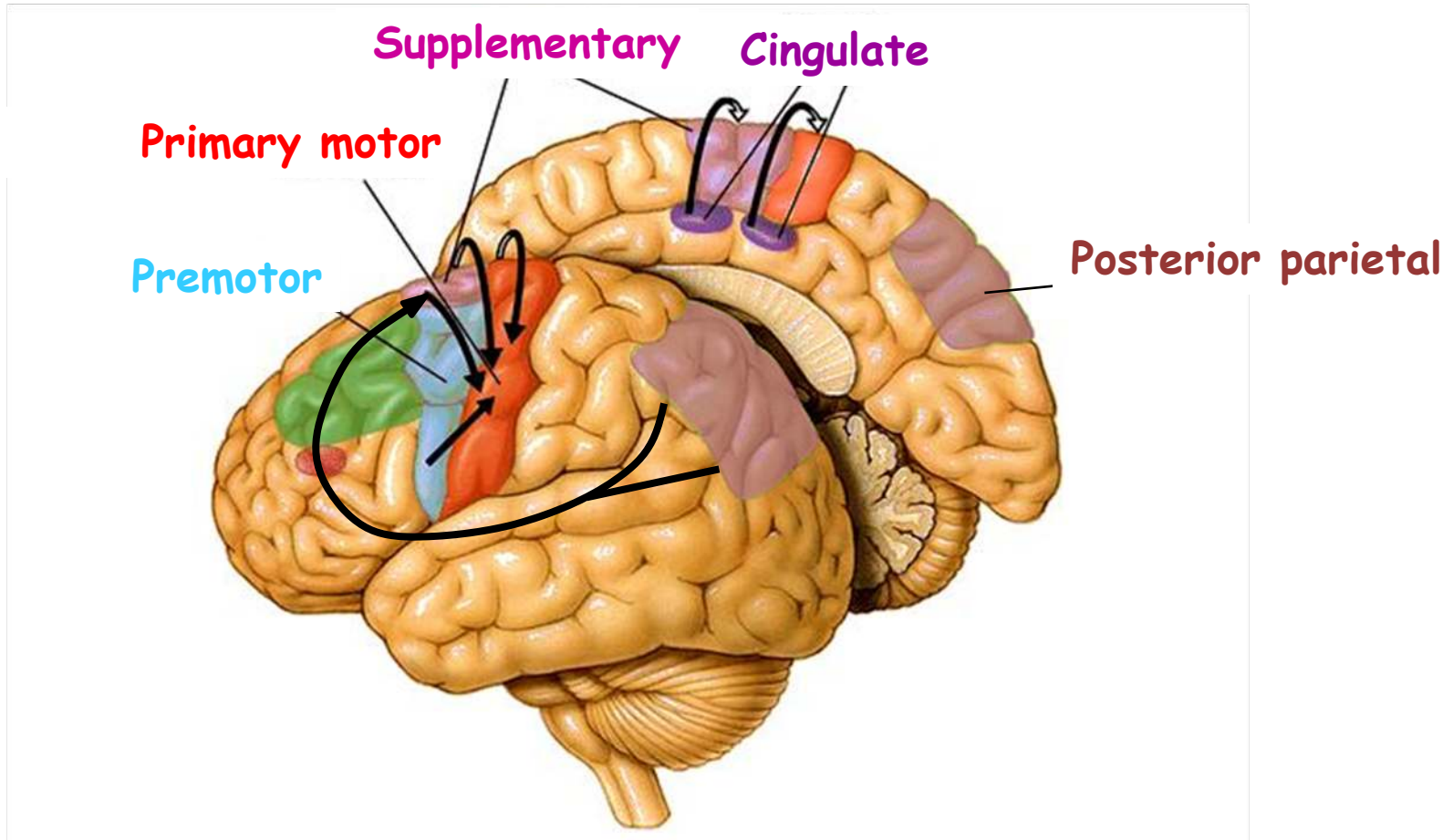
Organization of movement

motor cortex (supplementary, premotor)
system of the basal ganglia
cerebellum

Execution of movement

"upper" motoneurons in the primary motor cortex
cortico-spinal pathway (pyramidal tract)
"lower" motoneurons in the spinal cord
peripheral nerves
neuro-muscular transmission of the impulse

Major cortical areas participating in motor control



Representation of different regions of the body in the primary motor cortex

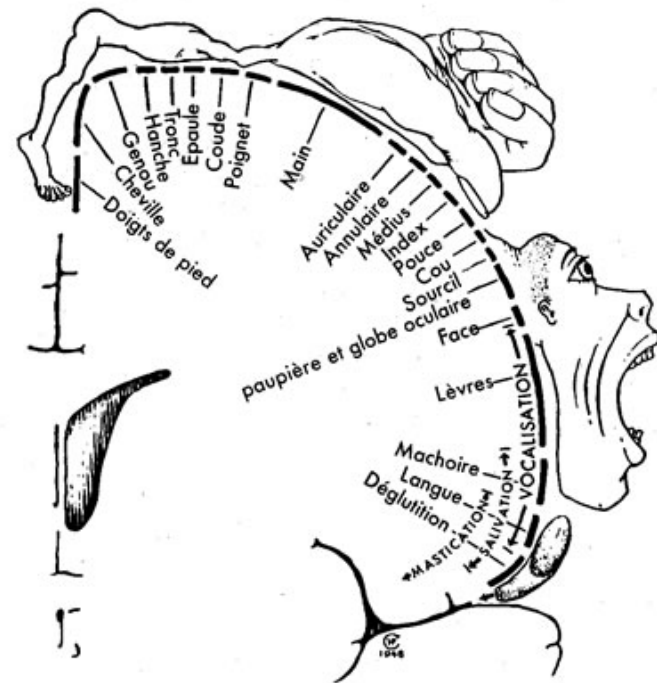


Figure 150 Δ

Homunculus moteur (Penfield et Rasmussen, 1957, p.57, figure 22)

Functions of the various cortical motor areas

1. Primary motor cortex

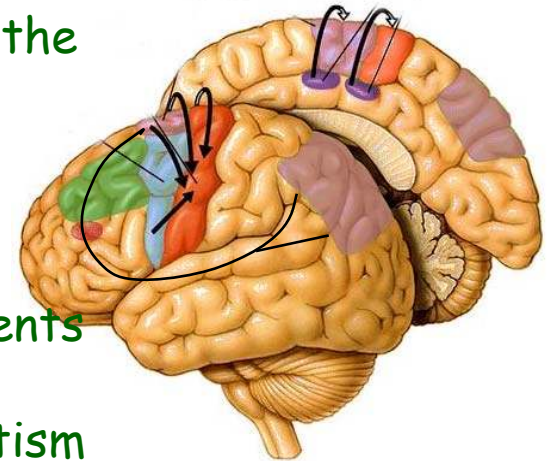
- It coordinates muscle contractions
- It determines the temporal process of muscular activation
- Downstream information of motor centers about the planned movement

2. Premotor cortex

- It controls movements triggered by visual and auditory stimuli
- Postural settings necessary to carry out movements
- It facilitates the subsequent motor response
- Lesions in this brain region results in akinetic mutism

3. Supplementary motor cortex

- It transfers sensory informations triggered by movements to the primary motor cortex
- It ensures coordinated muscle actions during complex movements
- It prevents mirror movements
- It influences motor control of the spinal cord



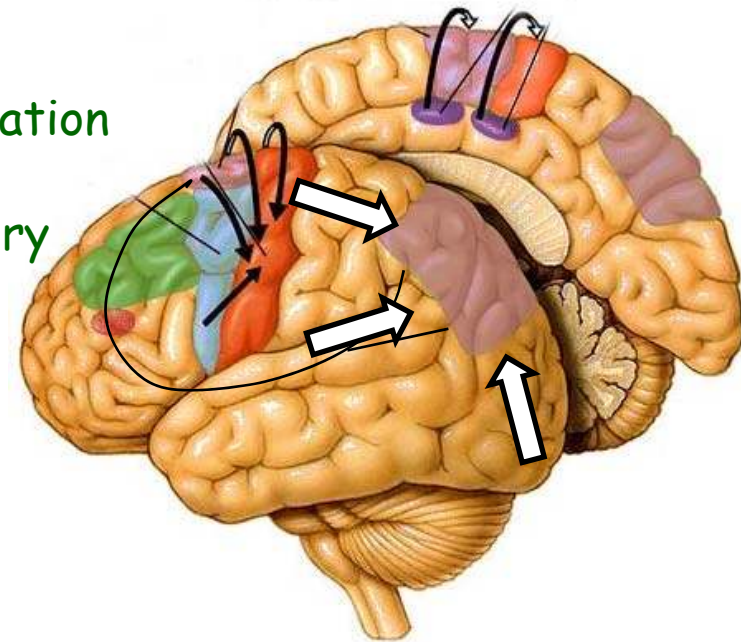
Functions of the various motor cortical areas

4. Cingular motor cortex

- It plays role in the planning and initiation of movements
- It integrates motor actions related to emotions

5. Posterior parietal cortex

- It provides important environmental information to carry out movements
- It collects visual, auditory and somatosensory informations about
 - the position of different body parts
 - the position of external objects
- It transfers information to the dorsolateral prefrontal cortex and the frontal eye field



Emotions trigger similar motor patterns in humans and primates



Anger, surprise, disgust, joy, despair, fear -
different emotions evoke similar motor patterns in individuals



The most important
executive motor system is

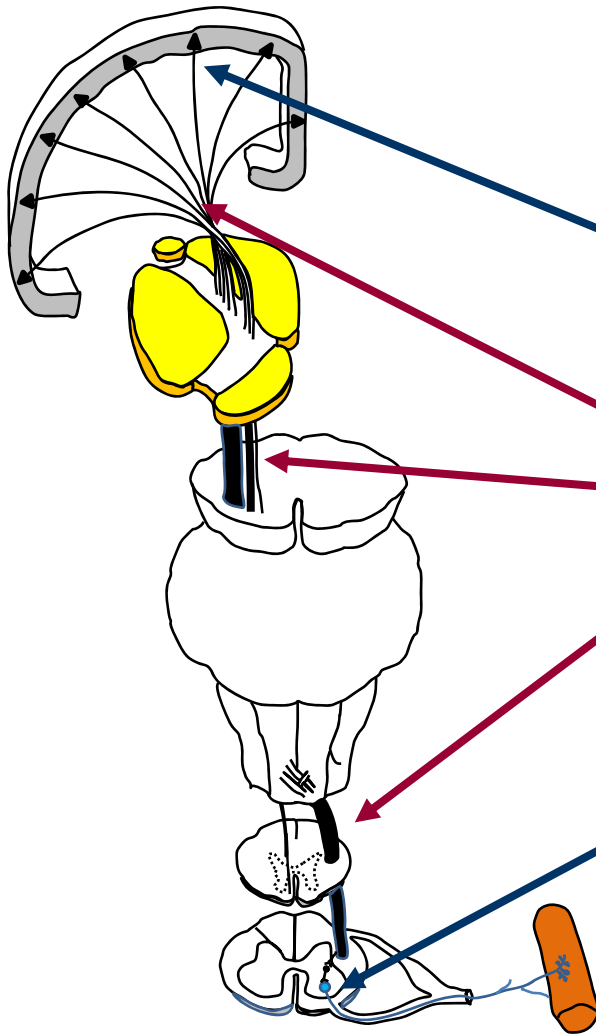
the pyramidal tract

upper motoneuron

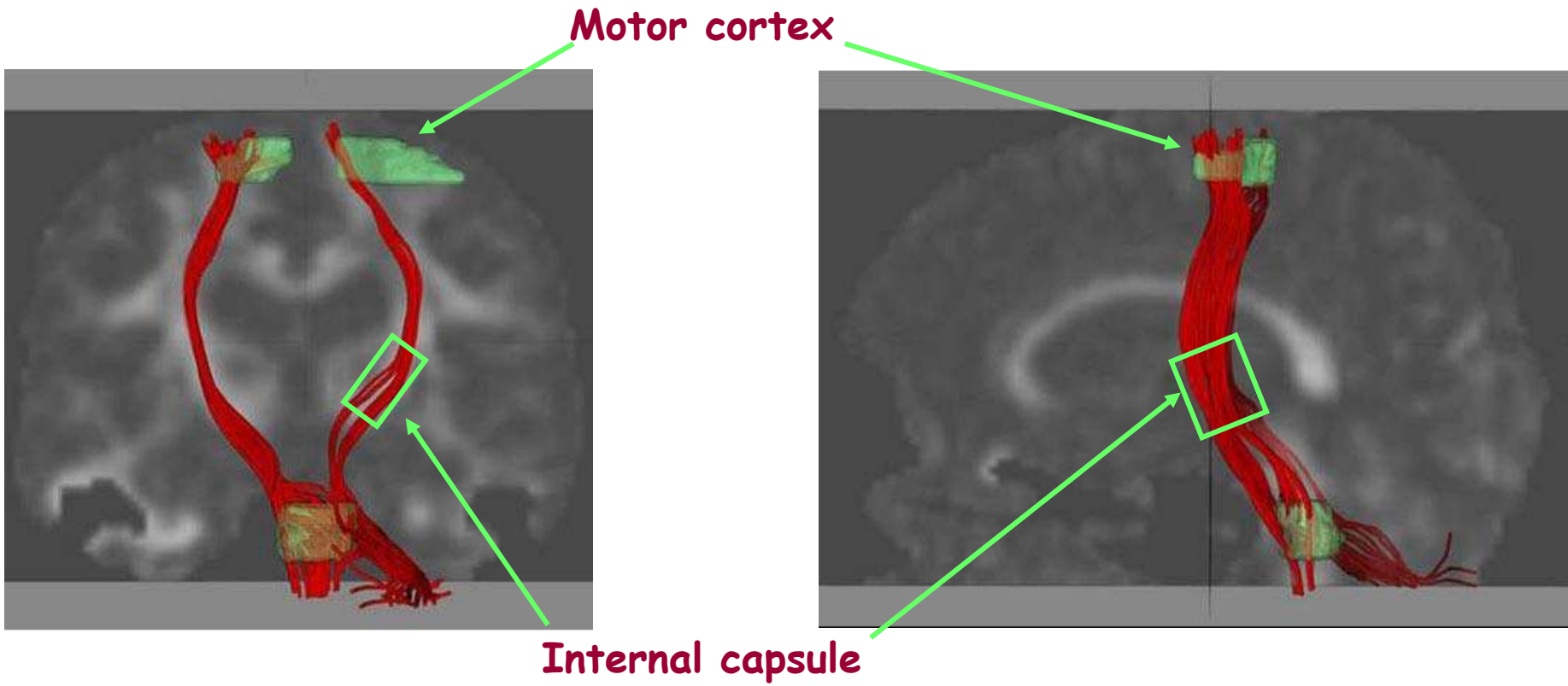
pyramidal tract

lower motoneuron

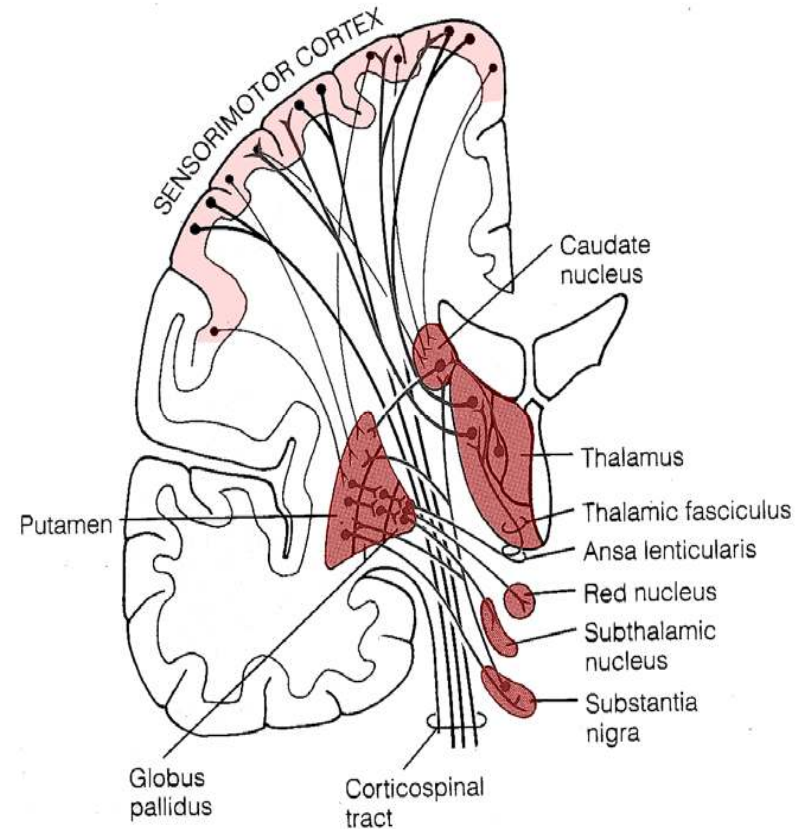
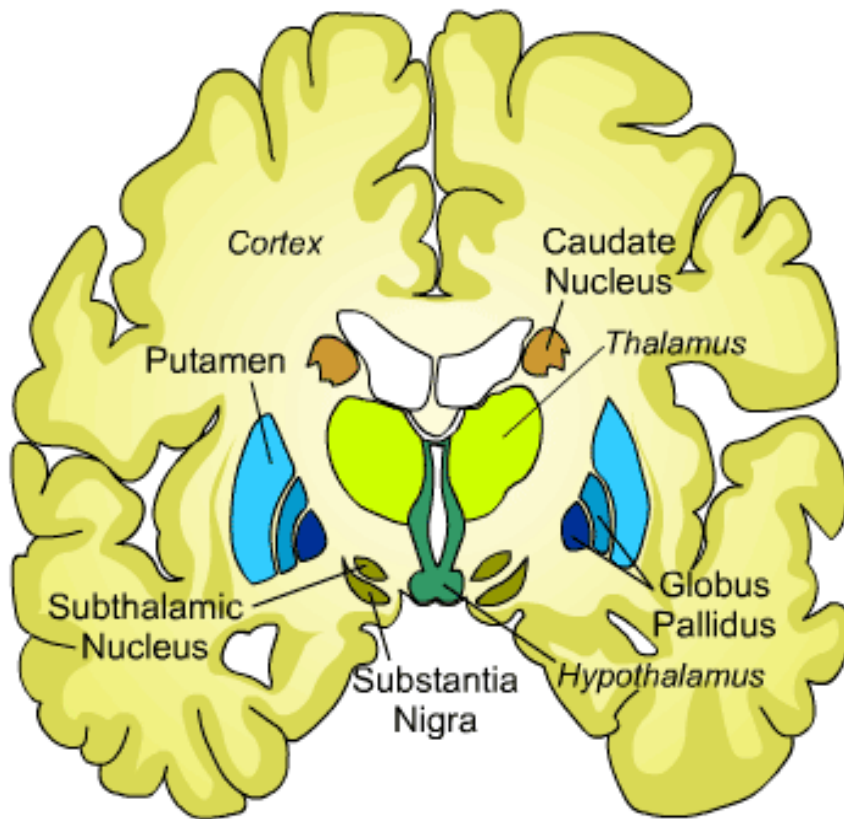
Its lesion results in reduction
(paresis) or complete loss
(paralysis) of muscle power.



The pyramidal tract can be visualised in MR scans (tractography programs)

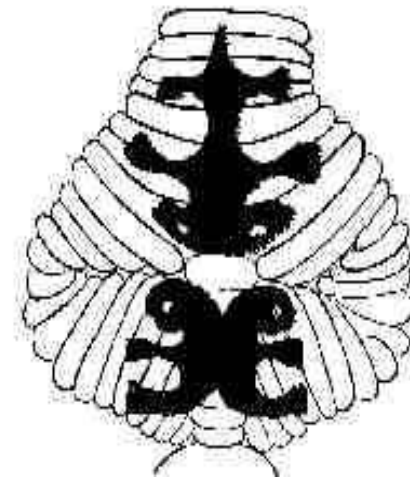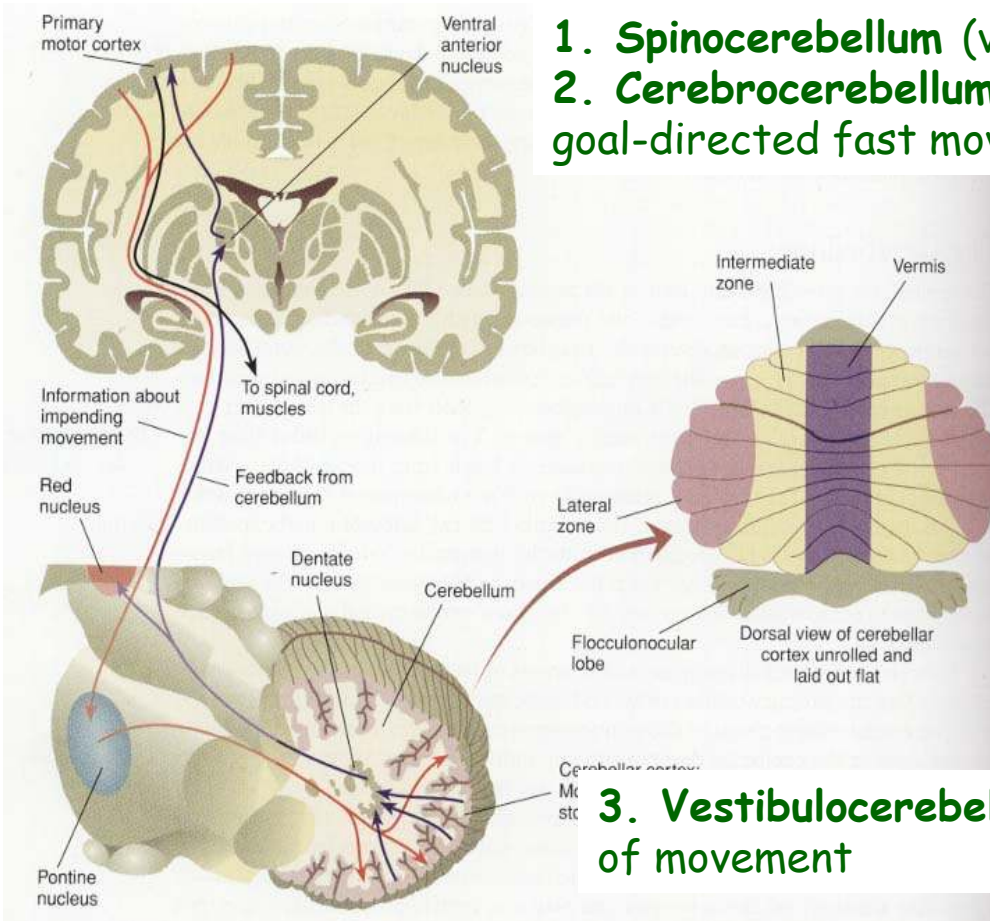


Subcortical structures of movement control: the basal ganglia



Cerebellar system of the movement control

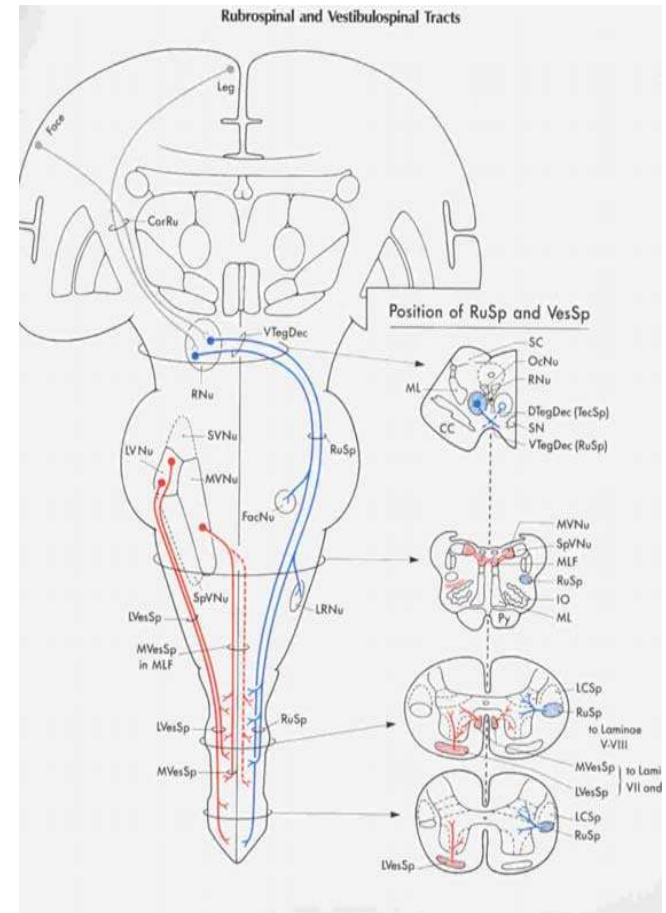
1. **Spinocerebellum** (vermis, intermedier zone): balance, gait
2. **Cerebrocerebellum** (cerebellar hemispheres): accuracy of goal-directed fast movement



3. **Vestibulocerebellum** (flocculonodular): spatial organization of movement

Descending motor pathways in the brainstem

- 1. Vestibulo-spinal tract:** It originates from brainstem vestibular nuclei, affects lower motoneurons via interneurons in the spinal cord. It mediates postural reactions; activates extensor and inhibits flexor motoneurons.
- 2. Cortico-reticular and reticulospinal pathways:** They regulate muscle tone (supplementary motor cortex - reticular system - spinal cord α and γ motoneurons).
- 3. Tecto-spinal and rubro-spinal pathways:** They regulate muscle tone via spinal cord interneurons, and maintain head position and balance when fixing gaze.



Neuronal circuits regulating movement

1. Striatal circuit

cerebral cortex (motor, sensory) - striatum - thalamus (VA, VL) - supplementary, premotor and primary motor cortex

It regulates the direction and extent of movement.

2. Cerebellar circuit

motor cortex - pons - cerebellar cortex - deep cerebellar nuclei - thalamus VL - motor cortical areas

It regulates initiation of movement and coordination of co-acting muscles.

CORTEX → → **THALAMUS** → **CORTEX**

Examination of the motor system

Muscle tone: the normal state of balanced tension in the relaxed muscle. The appropriate muscle tone is the prerequisite of precise motor control.

Muscle volume (trophy): it is influenced by several undetermined factors, any disturbance in the neuro-muscular transmission results in a reduction of muscle mass.

Muscle power (strenght): the extent of work that can be carried out by a given muscle.

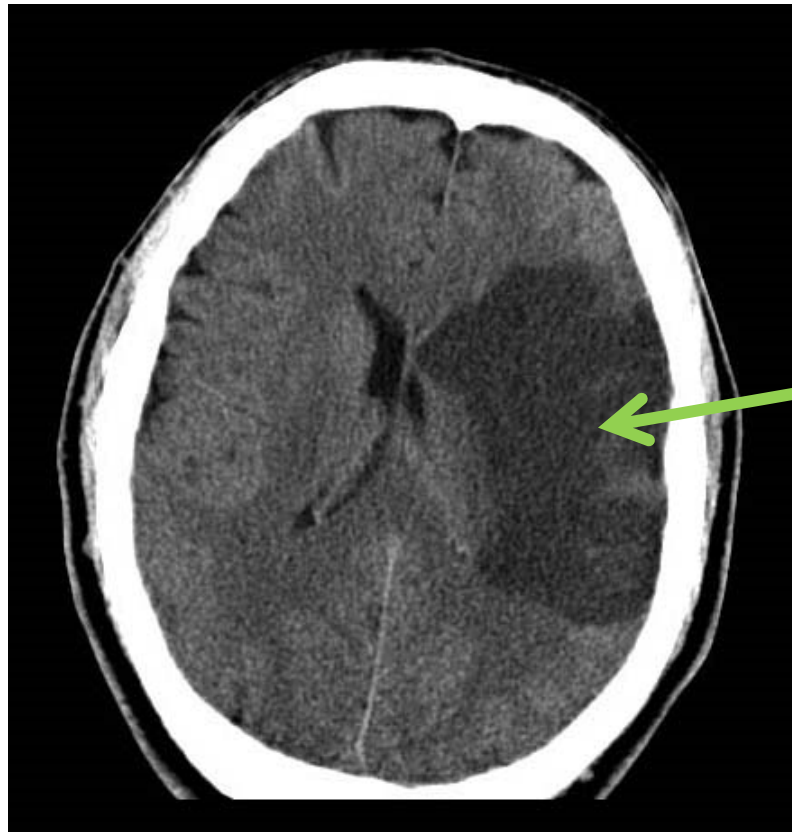Stretch reflexes: muscles contract in response to stretch. The stretch reflex may exaggerate or vanish under pathological conditions.

Symptoms of pyramidal tract injury: various pathological reflexes, such as Babinski's sign, indicating a lesion of the pyramidal tract.

Coordination of movement: capability to carry out goal-directed movements, which is ensured by the collaboration of motor, sensory and association systems.

Middle cerebral artery stroke in the left hemisphere causes right sided hemiparesis

Right



Left

Symptoms of the patient

Negative deficits:

In response to the order of the examiner:

- the patient is unable to move the right extremities (arms, legs)
- the patient is unable to smile symmetrically (mouth is pulled to the left)

Positive deficits:

In response to the examiner's action:

- the patient exhibits spastic muscle tone (fingers and elbow on the right side are flexed)
- the patient exhibits pathological reflexes (Babinski reflex, clasp-knife phenomenon)

Disorders of the basal ganglia: Parkinson's disease

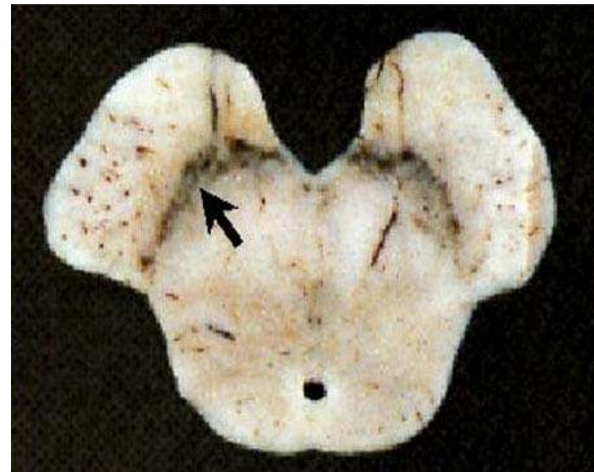
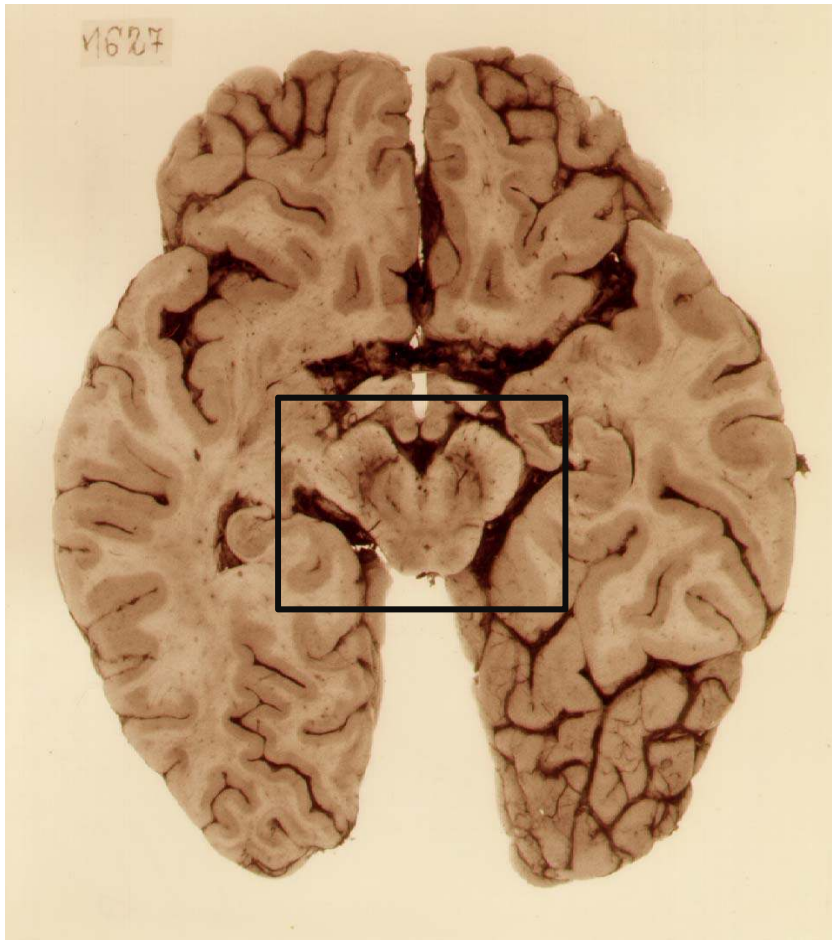
A neurodegenerative disease with unknown etiology.

Main pathological characteristic is the loss of *dopaminergic neurons* in the substantia nigra.

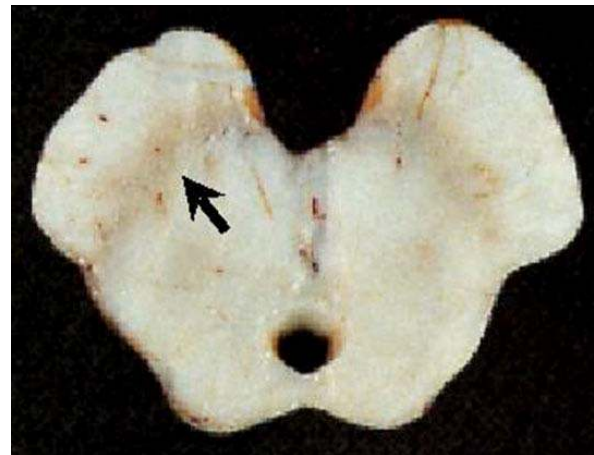
The *dopaminergic*, noradrenergic, serotonergic and cholinergic neurotransmission is disturbed.

Serious motor and non-motor symptoms emerge.

Pathological changes in the brain



**Normal
substantia
nigra**



**Loss of
dopaminergic
cells in the
substantia
nigra in
Parkinson's
disease**

Motor symptoms


Tremor (resting)

Muscle rigidity

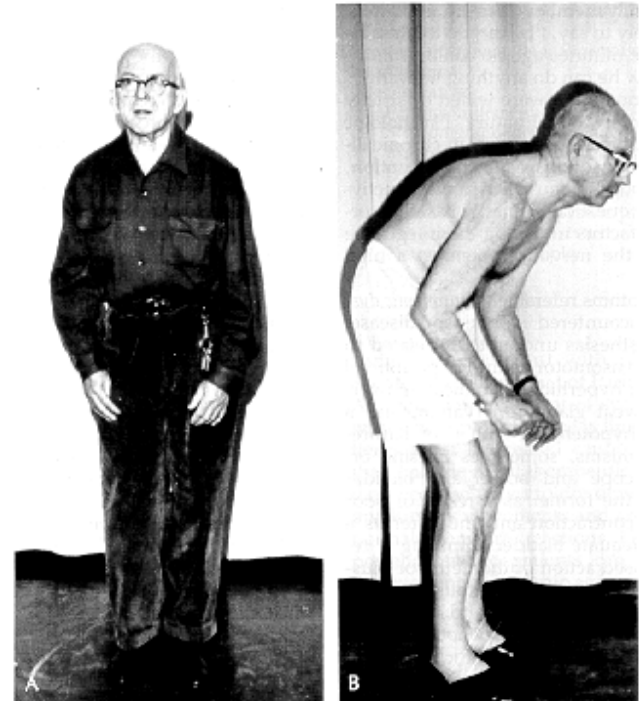
Disturbance of posture

Disturbance of movement initiation (akinesia)

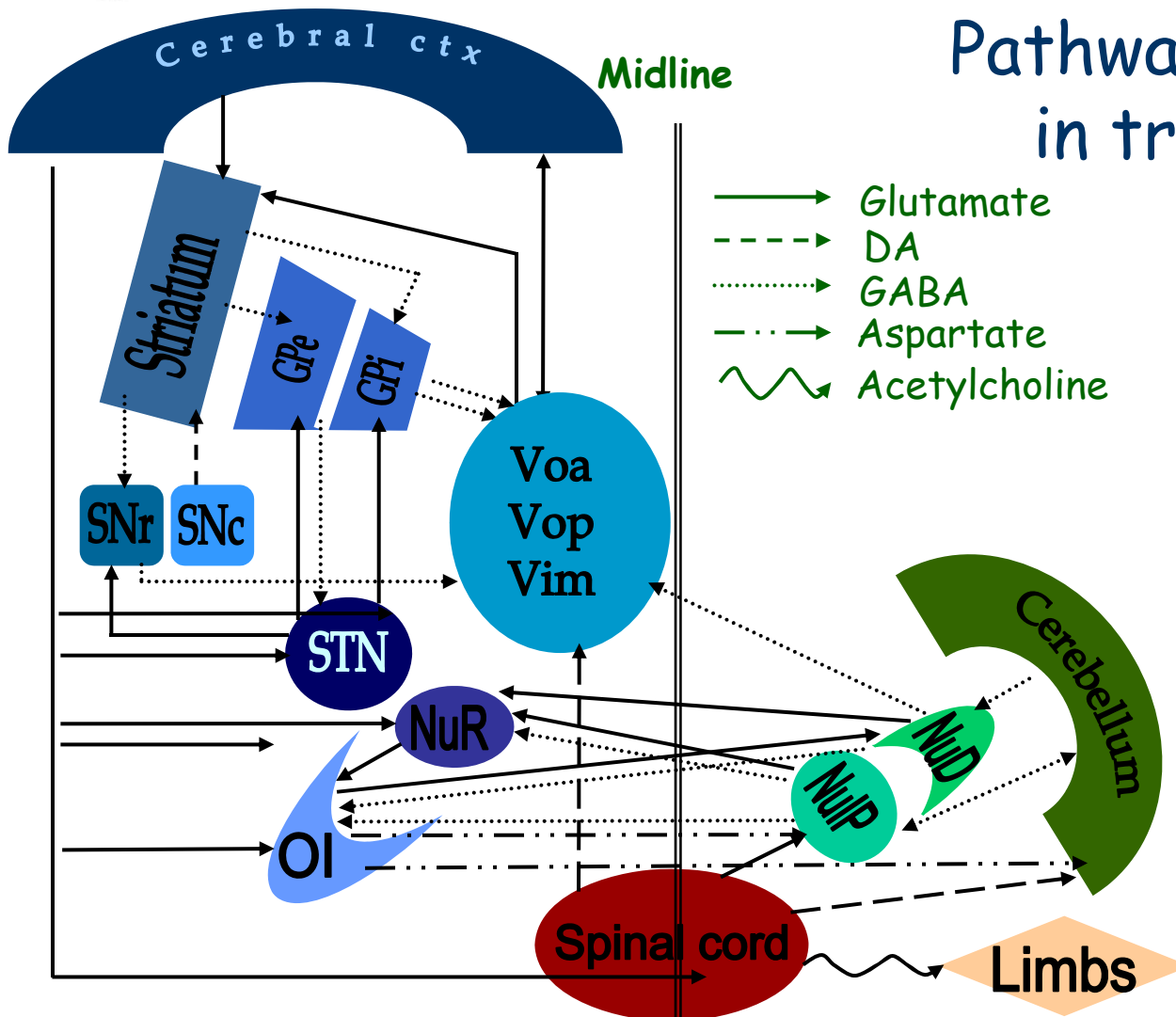
Slowing of movement (bradykinesia)



Charcot's
"vibratory
chair"



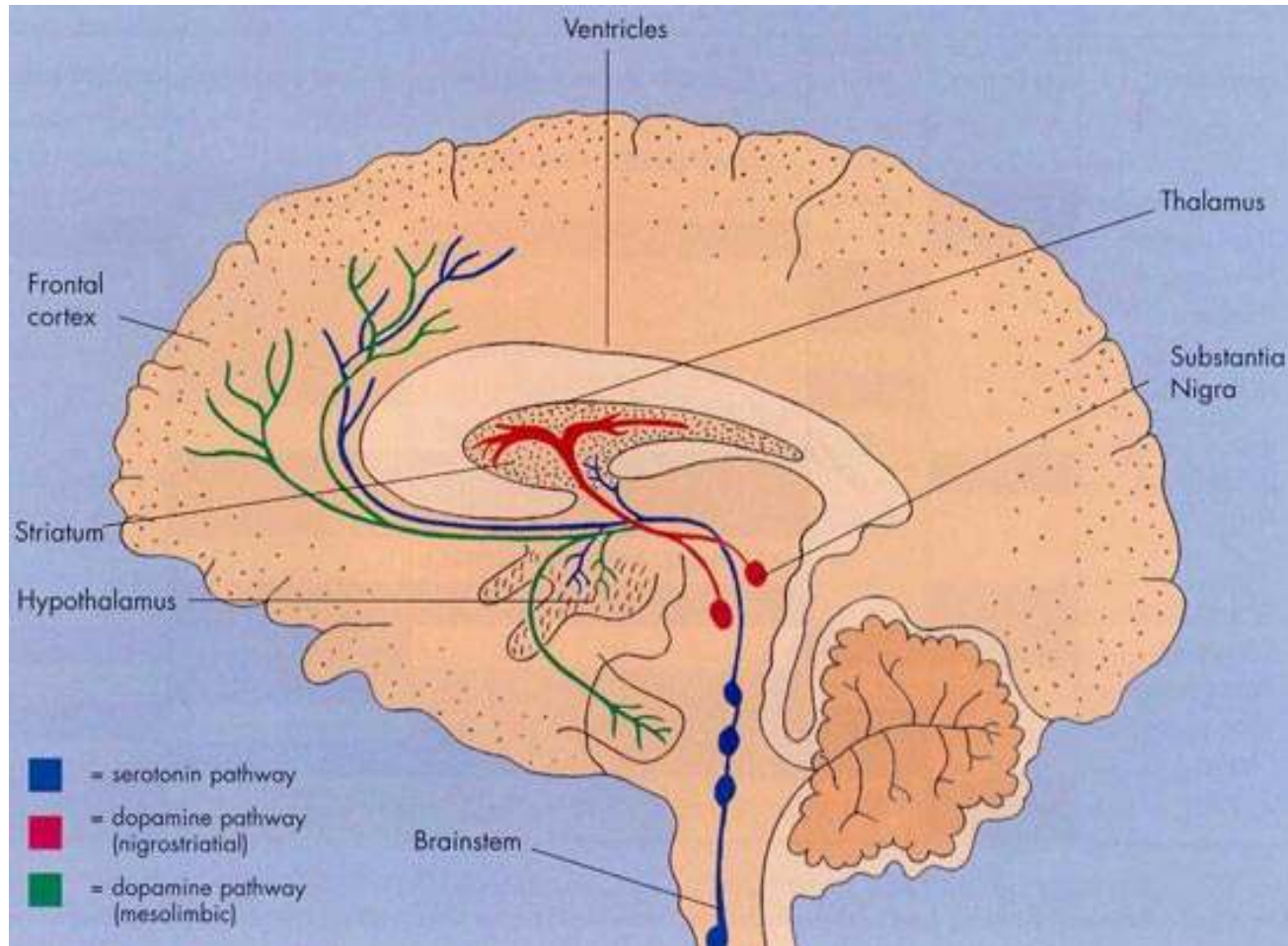
Pathways participating in tremor genesis



- Glutamate
- - - - - DA
- ⋯⋯⋯ GABA
- · - · - Aspartate
- ~ Acetylcholine

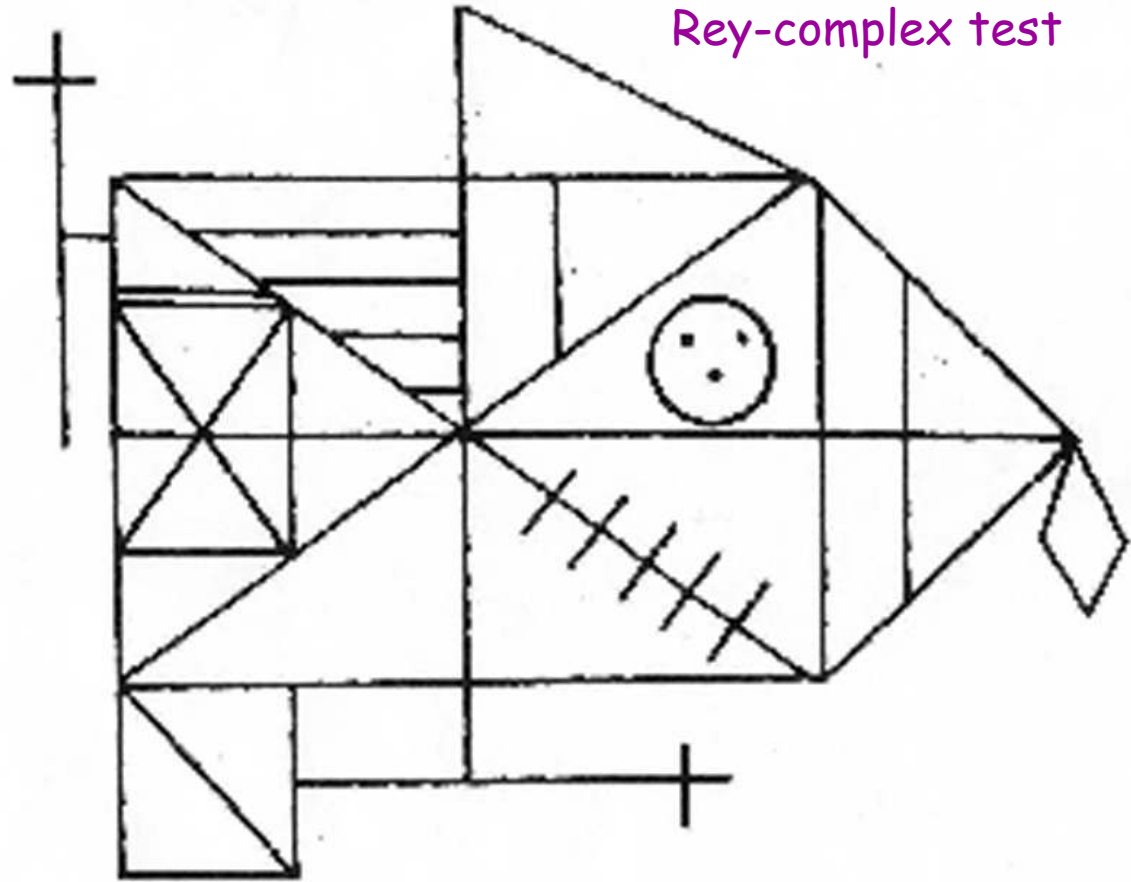
- GPe: globus pallidus ext.
- GPI: globus pallidus int.
- SNc: subst. nigra p. comp.
- SNr: subst. nigra p. ret.
- VLa: nucl.ventrolat. thal.
- VLp: nucl.ventropost. thal.
- STN: nucl. subthalamicus
- NuR: nucl. ruber
- OI: oliva inferior
- NuD: nucl. dentatus
- NuIP: nucl. interpositus

Ascending monoaminergic pathways

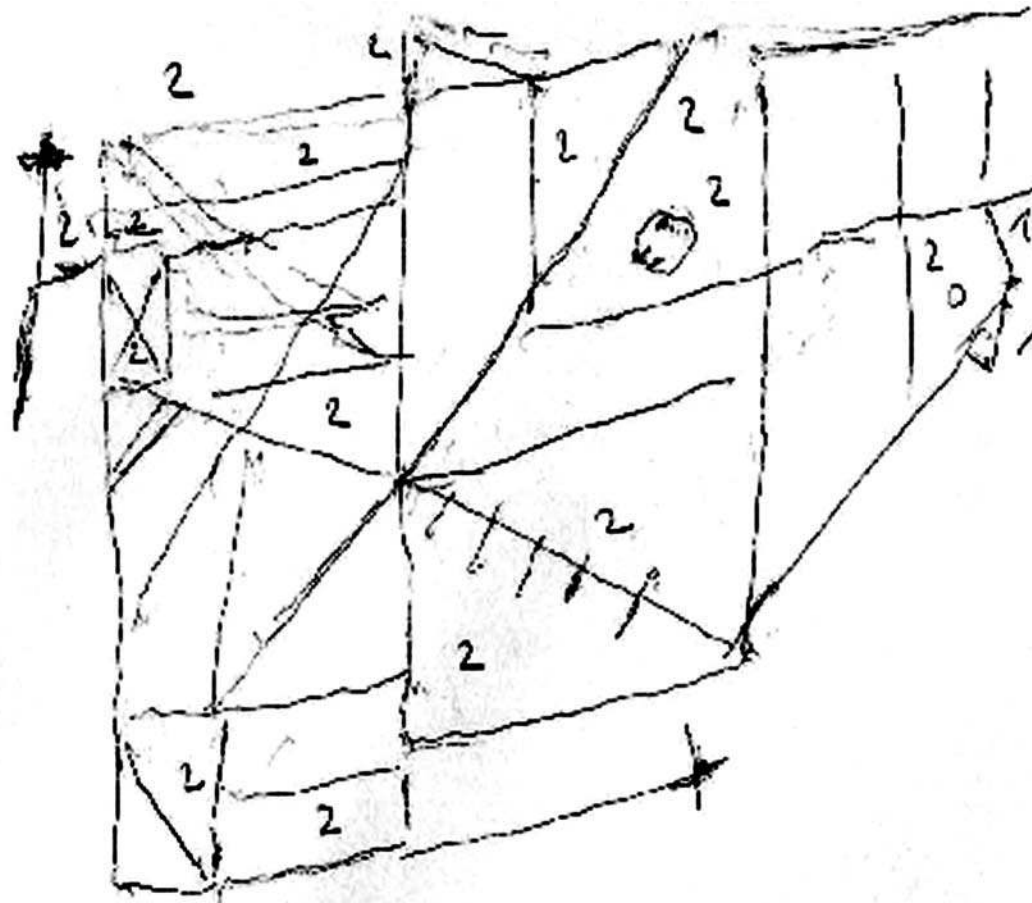


Non-motor symptoms (cognitive disturbances)

Working memory
Problem solving
Planning
Execution
Attention
Emotional life
Speech



Recall of the Rey-complex in Parkinson's Disease



Disorder of the cerebellar motor system

1. Spinocerebellar ataxia

It is genetically determined group of diseases (9th chromosome).

Degeneration of the posterior bundle of the spinal cord, the spinocerebellar and the cortico-spinal pathways.

Symptoms: limb- and trunk ataxia, ataxic gait, paresthesia, ocular movement disorder etc.

2. Essential tremor

Its etiology is not known. Very likely that it is caused by the functional disturbance of both the brainstem and cerebellar motor control systems.

Symptoms: postural and intention tremor, tremor of the head and vocal cords.

The „cognitive” movement disorder: Apraxia

The goal-directed motor acts are the result of the synthesis of elementary movement patterns.

Execution of complex movements requires sufficient muscle force, muscle tone, intact coordination and sensory systems.

Preceding the motor actions it is necessary to design a motor plan.

Apraxia is the result of a brain injury, which makes patients incapable to carry out goal-directed movements, to execute learned complex movements, to coordinate the movements of the limbs, while they do not exhibit any muscle weakness, functional disturbance of coordination or the sensory system, and they do understand the task.

Types of apraxia

Ideomotor: the patient is unable to imitate the action without the presence of the corresponding objects

Ideator: the patient is unable to plan complex movements, consequently the execution is often interrupted

Kinetic: the patient is unable to carry out fine movements

Constructive: the patient is unable to execute tasks requiring spatial recognition even using eye control

Dressing apraxia: the patient is unable to properly dress up.

The end